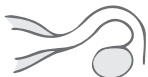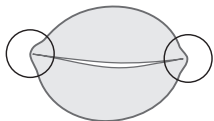


Pre-Scan

Locate

transverse

- Endometrial stripe
- Cornua
- RT & LT adnexa
- RT & LT tubal course



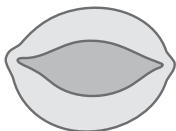
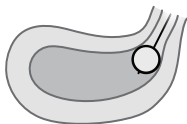
Perform a complete transvaginal ultrasound per your practice guidelines.

Uterine Cavity Assessment—SIS (Optional)

Scan uterine cavity

sagittal/transverse

Document normal and abnormal findings.



If applicable:

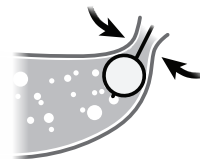
- Evaluate abnormalities using color Doppler.
- Evaluate for anomalies using 3D imaging.

Fallopian Tube Assessment

Locate cervix

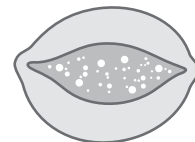
sagittal

Focus on cervix to confirm no backflow.



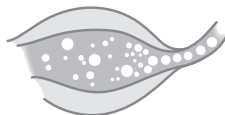
Obtain cornual view

transverse



Focus at Cornu

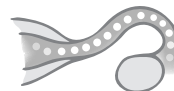transverse



Contrast entering tube

Slowly scan to Adnexa

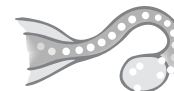transverse



Contrast through tube

Focus at Ovary

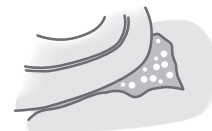transverse



Contrast exiting tube

Evaluate Cul-de-sac

sagittal



Bubbles in cul-de-sac

Repeat to evaluate contralateral tube

If no contrast flow visible into the tube, consider change in patient's position: roll patient slightly onto left side to observe flow in right tube and vice versa.